

Congenital ear malformations: Effectively correcting cryptotia with neonatal ear molding

September 18, 2017

by Collin Rozanski, BA; Joseph J. Rousso, MD

Cryptotia is a relatively common congenital ear malformation that can be difficult to correct with surgery. Treatment should be started before the first 6 weeks of life.

Facial Plastic Surgery Clinic

Cryptotia is an ear anomaly defined as a “pocket ear” because in this condition, the upper pole of the auricle is tucked in a pocket beneath the temporal skin.¹ Cryptotia is a common ear malformation among Asians, with an incidence of 1 in every 400 births in Japan.² Surgical correction of cryptotia can be very challenging and is usually not attempted before age of 5.

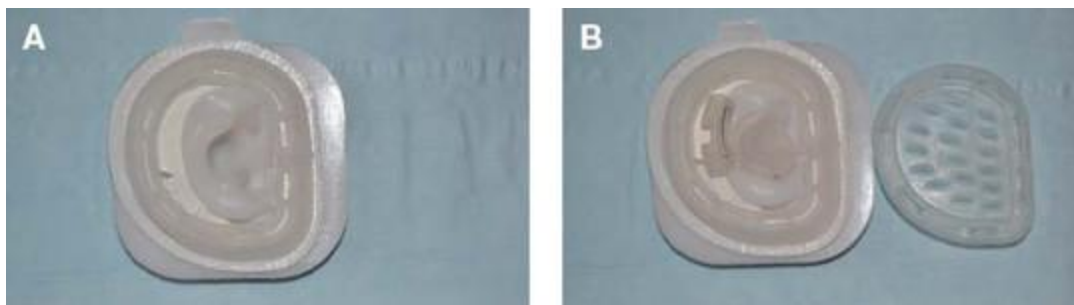
Ear molding with the EarWell Infant Ear Correction System (Becon Medical Ltd.; Naperville, Ill.) has been found effective for correcting ear malformations and reducing the need for surgery; it has been shown to provide superb rates of correction in newborns with congenital ear abnormalities, including those with cryptotia.^{3,4} Circulating maternal estrogen causes ear cartilage plasticity during the early weeks of life, making this the most effective time to begin molding. If treatment is started during this time, it can be completed in 2 weeks.⁵

An 8-day-old infant presented with her mother, who noted that her ears were misshapen; she was particularly distressed by the right-sided ear deformity, which appeared to be “buried.” History revealed a baby born at term without any significant comorbidities and having passed a hearing screening. Physical exam revealed a right-sided cryptotia whose cartilaginous structure could be manipulated out of its buried position. The decision was made to attempt ear molding for early correction of the cryptotic ear.

The hair-bearing skin around the ears was shaved to allow placement of the medium-sized EarWell cradle. Next, the cradle was placed around the right ear, with care taken to ensure that the posterior conformer was several millimeters away from the postauricular sulcus. [Note: When the posterior portion of the cradle is placed and secured, attention should be paid to the location of the posterior conformer and where the retractor(s) will be placed. The posterior conformer and the retractor(s) should never overlap, to avoid soft-tissue necrosis.]

The adhesive cover on the cradle was removed and the cradle gently secured to the periauricular skin. Next, the retractors were placed and secured with adhesives (part of the prefabricated EarWell system). The conchal former was then placed in the prefabricated orientation that leaves the external auditory canal unobstructed. Finally, the cap was placed to secure everything into the correct position and put pressure on the retractor(s) and conchal former. [Figure 1](#) shows how the cradle system is set up on a silicone ear model.

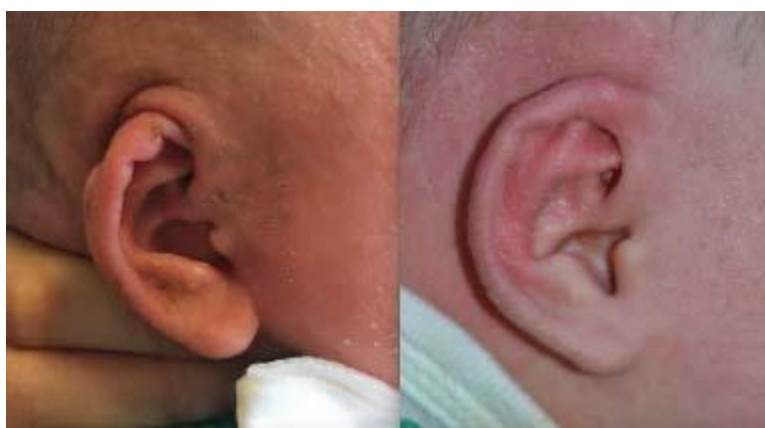Figure 1. A: Photo shows a medium-sized EarWell cradle fitted around a silicone right ear model. B: This photo shows the correct placement of a retractor and conchal former on the silicone model ear before placement of the securing cap (shown on the right).



The patient's mother was told to be cautious and return immediately if there were any signs of fever or discharge, to ensure that no yeast infection developed behind the ear.

After 2 weeks with the EarWell system in place, the cryptotia deformity was completely corrected and the superior helix was in the correct anatomic position. [Figure 2](#) shows the before-and-after treatment images.

Figure 2. The right-sided cryptotic ear malformation in a newborn is shown on the left. On the right, the patient is shown 2 weeks after therapy.



Cryptotia is a relatively common congenital ear malformation that can be difficult to correct with surgery. The EarWell Infant Ear Correction System provides a nonsurgical, safe, efficacious way to correct this malformation in neonates and should be considered by physicians when treating newborns presenting with ear deformities, including cryptotia. Ideally, the treatment should be started before the first 6 weeks of life.

Reference

1. Paredes AA Jr., Williams JK, Elsayh NI. Cryptotia: Principles and management. Clin Plast Surg 2002; 29 (2): 317-26.
2. Cho BC, Han KH. Surgical correction of cryptotia with V-Y advancement of a temporal triangular flap. Plast Reconstr Surg 2005; 115 (6): 1570-81.
3. Byrd HS, Langevin CJ, Ghidoni LA. Ear molding in newborn infants with auricular deformities. Plast Reconstr Surg 2010; 126 (4): 1191-1200.
4. Daniali LN, Rezzadeh K, Shell C ,et al. Classification of newborn ear malformations and their treatment with the earwell infant correction system. Plast Reconstr Surg 2017; 139 (3): 681-91.
5. Doft MA, Goodkind AB, Diamond S ,et al. The newborn butterfly project: A shortened treatment protocol for ear molding. Plast Reconstr Surg 2015; 135 (3): 577e-83e.

From Icahn School of Medicine at Mount Sinai, New York City (Dr. Rousso and Mr. Rozanski); and the Division of Facial Plastic and Reconstructive Surgery, Department of Otolaryngology-Head and Neck Surgery, The New York Eye and Ear Infirmary of Mount Sinai, New York City (Dr. Rousso).

Ear Nose Throat J. 2017 September;96(9):359-360