

The Newborn Butterfly Project: A Shortened Treatment Protocol for Ear Molding

Melissa A. Doft, M.D.
Alison B. Goodkind, B.A.
Shawn Diamond, M.D.
Jennifer I. DiPace, M.D.
Ashutosh Kacker, M.D.
Anthony N. LaBruna, M.D.

New York, N.Y.



Background: Secondary to circulating maternal estrogens, a baby's ear cartilage is unusually plastic during the first few weeks of life, providing an opportunity to correct ear deformities by molding. If molding is initiated during the first days of life with a more rigid molding system than previously described in the literature, the authors hypothesized that treatment time would be reduced and the correction rate would increase.

Methods: An interdisciplinary team identified and assessed all infants born with ear deformities at New York-Presbyterian Hospital/Weill Cornell Medical Center. The authors conducted a prospective, institutional review board-approved study on the first consecutive 100 infants identified. Parents were surveyed initially, immediately after treatment, and at 6 and 12 months.

Results: One hundred fifty-eight ears in 96 patients underwent ear molding using the EarWell Infant Ear Correction System. Eighty-two percent of the children had the device placed in the newborn nursery and 95 percent had it placed before 2 weeks of life. Average treatment time was 14 days, and 96 percent of the deformities were corrected. Complications were limited to mild pressure ulcerations. Ninety-nine percent of parents stated that they would have the procedure repeated.

Conclusions: The molding period can be reduced from 6 to 8 weeks to 2 weeks by initiating molding during the first weeks of life and using a more secure and rigid device. Through an interdisciplinary approach, the authors were able to identify patients and to correct the deformity earlier and faster than has been previously published, eliminating the need for surgical correction in many children. (*Plast. Reconstr. Surg.* 135: 577e, 2015.)

CLINICAL QUESTION/LEVEL OF EVIDENCE: Therapeutic, IV.

Children and adults with ear deformities experience significantly more psychological distress, anxiety, self-consciousness, behavioral problems, and social avoidance than those with normally shaped ears.^{1,2} Although otoplasty is a surgical option to correct ear deformities, there are potentially significant complications to this procedure, including residual deformity,

hematoma, cellulitis, and the need for additional surgery. During the neonatal period, ear molding is a proven, noninvasive alternative for babies born with abnormally shaped ears.³⁻¹⁰

During the first few days of life, the auricular cartilage has an unusual plasticity, because of circulating maternal estrogens; these hormones peak at day 3 and return to baseline during week 6. It is hypothesized that hyaluronic acid, a key component in ear cartilage, is elevated by circulating estrogens and is responsible for the malleable nature of the newborn ear. Therefore, there is a short, privileged time during which ear deformities can be corrected without surgical intervention.³

Clinicians have demonstrated that up to 30 percent of newborns born with an ear deformity will self-correct.^{3,11} However, there is no

From the Division of Plastic Surgery, Department of Surgery, and the Departments of Pediatrics and Otolaryngology, New York-Presbyterian Hospital/Weill Cornell Medical Center. Received for publication June 9, 2014; accepted August 8, 2014.

Presented at the American Academy of Pediatrics 2012 National Conference and Exhibition, in New Orleans, Louisiana, October 20 through 23, 2012; The Aesthetic Meeting 2012, in Vancouver, British Columbia, Canada, May 3 through 8, 2012; the 2012 New York Regional Society of Plastic Surgery Resident's Night, New York, New York, March 12, 2012; and the 2012 Plastic Surgery Senior Resident's Conference, in Tampa, Florida, January 18–21, 2012. Copyright © 2015 by the American Society of Plastic Surgeons

DOI: 10.1097/PRS.0000000000000999

Disclosure: The authors have no financial interest to declare in relation to the content of this article. No external funding was received.

scientific method of predicting which cases these will be.^{10–12} Moreover, it has been observed that molding is more successful when initiated before the infant is 6 weeks old.^{3,5} Without early correction, many children will require otoplasty during childhood.

Previously, ear molding has required the use of various molds, feeding tubes, surgical tapes, and splints, which are cumbersome for mothers and difficult to keep in position.^{5–8,10,13–15} The EarWell Infant Corrective System (Becon Medical Ltd., Naperville, Ill.) is an approved adhesive appliance that attaches to the child's skin to mold the ear into a normal anatomical shape. A recent study revealed that this device corrects 90 percent of all infant deformities with better aesthetic detail than was achieved with previous molding techniques or through surgical intervention.³

This article presents our experience in treating 100 consecutive infants using the EarWell Infant Corrective System, a more rigid device than what was previously used. We hypothesized that early capture and treatment of ear deformities would reduce the molding period and improve outcomes. This study also examines the parents' perspectives to improve on prior studies and to refine indications and limitations of ear molding.

PATIENTS AND METHODS

In the well-baby newborn nursery of New York-Presbyterian Hospital/Weill Cornell Medical Center, the pediatric staff identified ear deformities during the initial physical examination and

referred patients to the senior author (M.A.D.) for evaluation. A prospective, institutional review board–approved study was conducted on the first consecutive 100 patients with ear deformities that were amenable to molding. The children had only deformational abnormalities, in which the anatomy of the ear could be corrected if digital pressure was applied. All children were screened for hearing before evaluation for molding. All children in the study had normal hearing screens. The children were screened for comorbidities by chart review and parent report.

Children with varying deformities were invited to participate in the study; deformities included constriction, cryptopia, helical rim, prominent, conchal strut, and Stahl deformities. Children were excluded from the study if they had microtia, were older than 6 weeks, weighed less than 5 lb, were younger than 34 weeks' gestational age, and/or required advanced care in the neonatal intensive care unit.

The EarWell Infant Ear Correction System was used to mold each deformed ear, as it had shown superior results in the literature.³ The EarWell includes a cradle, retractors, conchal former, and a cap (Fig. 1). The device is made in both a medium and large size. It is a prefabricated device that is then modified to fit the baby. Retractors and a conchal former are carefully placed to correct the baby's unique ear deformity. The device cradle encircles the ear by adhering to the infant's skin. The posterior strut of the cradle supports and reforms the superior crus of the antihelix. The retractors place tension on the helix to round a misshapen rim

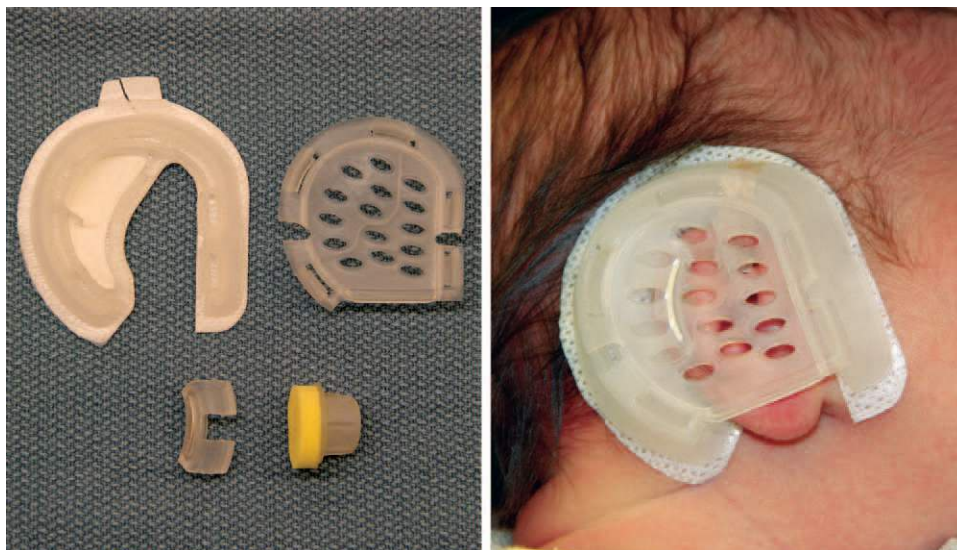


Fig. 1. The EarWell Corrective Infant System is composed of an anterior (cap) and posterior cradle, retractor, and a conchal former (left). A newborn baby with the EarWell in place (right).

and to create a concave scaphoid fossa. The conchal former is used to correct a prominent conchal strut. The cap secures the device and places a constant pressure on the retractors. If there is blanching of the ear skin, gauze can be added to reduce the pressure. It is important to explain to parents in cases of unilateral ear deformities that the goal is to correct the anatomy of the deformed ear, not to guarantee symmetry between ears. Although after treatment most ears do appear symmetric, it is impossible to achieve absolute symmetry.

During the initial patient visit, standard pretreatment photographs were taken and the device was placed. Children wore the splints for 24 hours per day and had them changed only when the adhesive loosened. The patients were followed on a weekly basis during molding. Treatment continued until 1 week after normalization of the ear anatomy was achieved or until 6 weeks of treatment. The treatment was also stopped if serious skin irritation or skin ulceration occurred. Parents completed surveys during the initial visit, at the final visit, and after the follow-up periods of 6 and 12 months. Correction of an ear deformity was evaluated by the clinical judgment of attending plastic surgeons and parental assessment. Before completing the postprocedural assessment of correction, parents reviewed preprocedure and postprocedure photographs and compared these photographs to a photograph of an anatomically normal ear. Attending plastic surgeons also reviewed the preprocedure and postprocedure photographs to confirm parental assessment.

The parents completed the surveys, which documented patient demographics, family history, satisfaction, ease of use, and complications. The surveys were based on questions asked in the Glasgow Children's Benefit Inventory,¹⁶ the Infant Toddler Quality of Life tool,¹⁷ and previous ear molding studies.^{2,3}

RESULTS

There were 100 consecutive patients treated with the EarWell System from December of 2010 to February of 2013. Fifty-four percent of patients were boys and 46 percent of patients were girls. Four patients were excluded from the study results. Of these four, three children were older than 6 weeks and one set of parents stopped treatment after 4 days, as they did not like the appearance of the device. In total, 158 ear molding procedures were included in this study on 96 patients.

The majority of participants were Caucasian (69 percent). Other ethnicities represented

included Asian (15 percent), Hispanic (4.5 percent), Indian (5 percent), Middle Eastern (4 percent), African American (2 percent), and an unknown donated egg (0.5 percent). Ninety-one percent of participants did not have a familial history of ear deformities and 9 percent reported a first-degree relative with a deformity. Sixty-one percent of the children were first born. Sixty-six percent of babies were delivered vaginally and 34 percent were delivered by means of cesarian birth. None of the children had serious comorbid conditions and there were no statistically significant maternal risk factors to develop a deformity (Table 1).

Table 1. Patient Demographics*

Category	No. (%)
No. of patients	96 (100)
Total no. of ears	158 (100)
Sex	
Male (total ears)	85 (54)
Female (total ears)	73 (46)
First born	
Yes	96 (61)
No	62 (39)
Ears	
Bilateral	62 (65)
Left	24 (25)
Right	10 (10)
Age at placement	
<1 wk	130 (82)
<2 wk	20 (13)
2–6 wk	8 (5)
Family history	
Yes	14 (9)
No	144 (91)
Baby comorbidities	
Hip dysplasia	2 (1)
Tethered tongue	2 (1)
Other (none requiring ICU care)	10 (6)
None	144 (91)
Pregnancy complications	
Diabetes	6 (4)
Breech	4 (3)
Preeclampsia	3 (3)
Short cervix	2 (1)
T-shaped uterus	2 (1)
Anemia	2 (1)
Elevated mercury	1 (1)
None	138 (87)
Maternal medications	
Synthroid	12 (8)
Insulin	5 (3)
Fertility treatments	4 (3)
Lexapro†	2 (1)
Zantac‡	2 (1)
None	133 (84)
Delivery method	
Vaginal	105 (66)
Cesarian	53 (34)

ICU, intensive care unit.

*The first 100 consecutive patients were included in the study. Four patients were excluded because of age older than 6 wk ($n = 3$) or short treatment time ($n = 1$). Numbers are based on the total number of ears.

†Forest Laboratories, New York, N.Y.

‡Boehringer Ingelheim, Ingelheim, Germany.

The treatment was initiated within the first 2 weeks of life for 95 percent of the infants. Eighty-two percent of devices were placed in the newborn nursery. Children were treated for a variety of deformities, including helical rim (38 percent), Stahl (25 percent), constricted ear (18 percent), cryptotia (18.5 percent), and prominent conchal strut (0.5 percent) (Fig. 2). The average treatment time was 14 days (range, 7 to 42 days). Ninety-six percent of parents rated the duration of molding as appropriate, 1 percent thought the treatment was too long, and 3 percent reported that it was not long enough.

Ninety-six percent of parents rated the outcomes as excellent or greatly improved (Fig. 3). Treatment was considered not successful for six infants who had recurrent deformities (two children) or who were only mildly improved (four children). Three percent of the children experienced mild pressure ulcerations that were treated with topical bacitracin or required no treatment. All parents were counseled about the possibility of a pressure sore occurring. Parents were asked to call the senior author (M.A.D.) if they noted a foul odor or discoloration of the adhesive. No parents reported that the pressure sore irritated the baby, but this is likely due to early detection of pressure sores by parents. None of the parents reported discomfort of their infant during the treatment.

The majority of parents (75 percent) were self-motivated to initiate ear molding to address the ear deformity. Others sought treatment based on their pediatrician's recommendation. Seventy-three percent of parents believed that their child's

deformity would lead to severe psychological harm. Families appreciated the ease of a noninvasive procedure and the avoidance of surgery. In 84 percent of the patients, the decision to treat was a joint decision made by both parents; in 9 percent, by only the mother; in 3 percent, by only the father; and in 5 percent, the decision involved the input of a grandparent.

One hundred percent of the participants rated the overall procedure as simple. Ninety-one percent of mothers breastfed their child during the treatment. None of the mothers believed that it was more difficult to feed the baby with the molds in place. Zero percent of participants reported that the device made the child more irritable, caused the baby pain, or upset the child. Most parents (93 percent) did not believe that people reacted negatively to the device when in public. Ninety-nine percent of patients stated that they were likely to repeat the procedure (Table 2).

DISCUSSION

Plastic surgeons, nurses, and mothers have been molding ears for centuries using homemade headbands, dental pastes, and Steri-Strips (3M, St. Paul, Minn.). Data have demonstrated that molding leads to lifelong anatomical changes if the ear can be corrected by 6 months of age.¹⁰ Although these techniques improve the anatomy of a misshaped ear to varying degrees, recent data have demonstrated that molding with a more rigid device such as the EarWell System leads to improved results likely due to a decrease in treatment interruptions from tapes and pastes falling

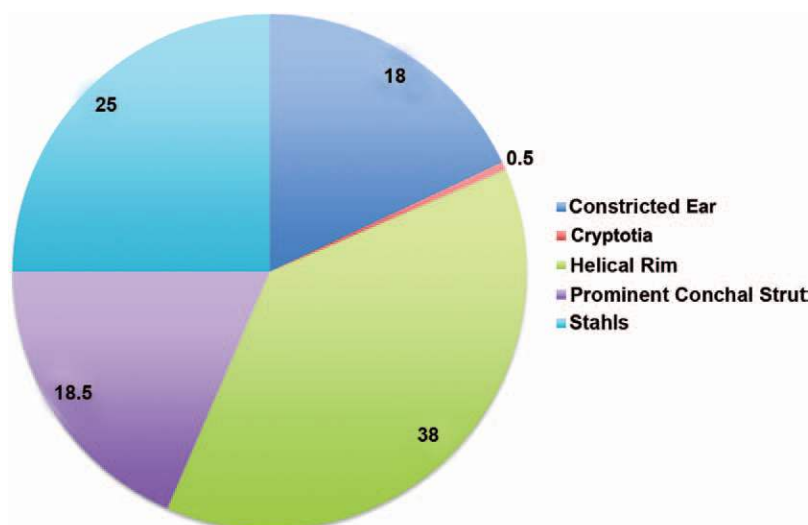


Fig. 2. In 100 babies, 158 ears were treated with a variety of ear deformities. The most common were helical rim and Stahl deformities.

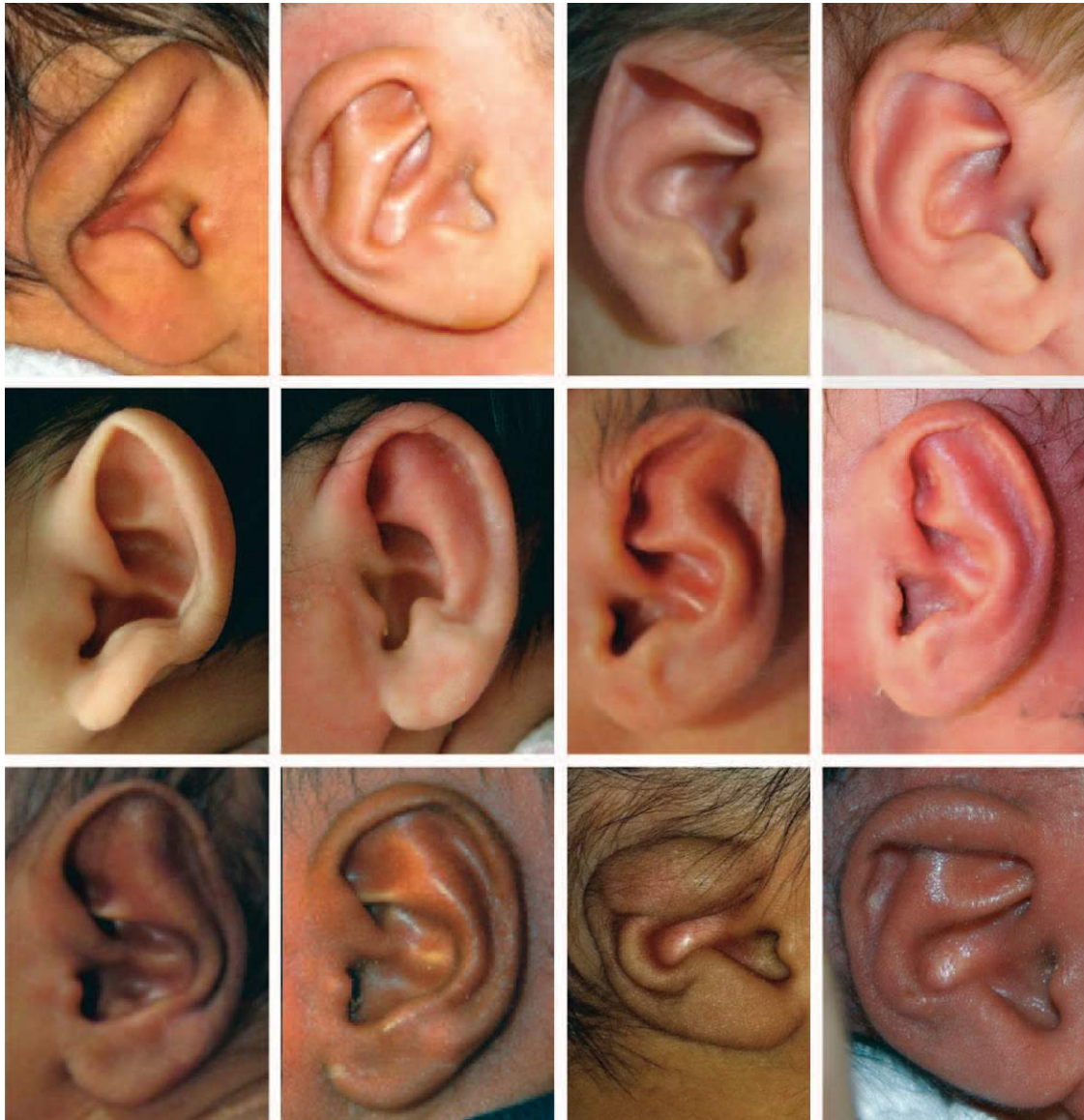

Fig. 3. Ninety-six percent of the parents rated the outcome from molding as excellent or greatly improved. Presented are examples of pretreatment (*left in each pair*) and posttreatment (*right in each pair*) photographs of a child with a constricted ear deformity (*above, left*), a helical deformity (*above, right*), a constricted ear deformity (*center, left*), a Stahl deformity (*center, right*), a Stahl deformity (*below, left*), and a helical rim deformity (*below, right*). Photographs were taken after 2 weeks of treatment. Correction was maintained for 2 years.

off and the ear being held in a stronger, more consistent mold.^{3,5-8,10,13,14} Underscored by scientific data, which documented that the ear cartilage is most pliable when circulating estrogens are elevated in the neonatal period, studies have demonstrated ear molding results are best if molding is started before 6 weeks of life.^{3,5,8} Fueled by these data, the current study aimed to capture babies at the peak of maternal estrogen levels and use a more rigid molding device to reduce treatment time and obtain a higher level of success than previously reported.

It is widely believed by pediatricians that ear deformities will often resolve without treatment. When observing newborn ear deformities, which were not treated, research has shown that only up to 30 percent will self-correct.^{3,13,18} Delaying treatment leads to a decrease in favorable outcomes, increasing the number of children seeking surgical correction.⁸ The small studies that demonstrate that molding is possible later in life require long treatment times (3 to 12 months), with poorer correction rates ranging from 18 to 70 percent.^{3,5-10,15,16} By identifying and treating patients

Table 2. Parents' Response to the Procedure*

Response	No. (%)
Decision maker	
Father	4 (3)
Mother	14 (9)
Mother/father	132 (84)
Mother/father/grandparent	8 (5)
Simplicity of device	
1 (difficult)	0 (0)
2	0 (0)
3	9 (6)
4	8 (5)
5 (very simple)	141 (89)
Feeding method	
Breast	100 (63)
Bottle	14 (9)
Bottle/breast	44 (28)
Caused pain	
5 (not really)	135 (85)
4	16 (10)
3	7 (4)
2	0 (0)
1 (yes, substantially)	0 (0)
Increased irritability	
5 (more irritable)	0 (0)
4	7 (4)
3	28 (18)
2	5 (3)
1 (less irritable)	118 (75)
People react negatively	
1 (yes, substantially)	2 (1)
2	8 (5)
3	24 (15)
4	39 (24)
5 (not at all)	85 (54)
Duration of molding	
1 (not long enough)	5 (3)
2 (appropriate)	151 (96)
3 (long)	2 (1)
Rating after molding	
5 (excellent)	111 (70)
4 (improved)	41 (26)
3 (mildly improved)	4 (3)
2 (recurrent)	2 (1)
1 (worse)	0 (0)
Likely to repeat molding	
5 (very likely)	146 (92)
4	9 (6)
3	1 (1)
2	2 (1)
1 (not likely at all)	0 (0)

*Based on total number of ears.

early, 96 percent of ear deformities were corrected with 2 weeks of treatment. This study demonstrates the benefits of initiating molding during the early neonatal period and the necessity of collaboration between pediatricians and plastic surgeons.

It could be argued that if 30 percent of patients will self-correct, 30 percent of children were unnecessarily treated. Unfortunately, there is currently no scientific method to predict which deformities will and will not improve. All parents were presented with data explaining that it was possible that their child's ear might improve without intervention and given the option of delaying

treatment for 1 to 2 weeks to observe the ear. Overall, most parents did not want to delay treatment, understanding that the treatment period was short and that the best results occur the earlier treatment is introduced. When presented with the option of a 30 percent chance of improvement with no treatment versus an over 90 percent chance of improvement through treatment, parents did not hesitate to opt for a noninvasive, low-risk procedure. Furthermore, in comparing molding to surgical correction, early intervention with molding has a 4 percent rate of residual deformity compared with a 10 to 24 percent rate with surgery.¹⁹

Although the residual deformity rate was lower than previously presented, there were six children who failed treatment by only improving mildly or having a recurrent deformity. Of the six children that failed, two had a first-degree relative with an ear deformity. These children outgrew their corrections between 3 and 4 months when the concha began to overgrow at an obtuse angle from the scalp. It is our belief that these children had a genetic predisposition to have a prominent ear. The remaining four ears had a constricted deformity, in which the skin did not allow complete correction of the cartilage. These children were molded for a total of 6 weeks, but without success. Children with Stahl deformities, cryptotia, helical rim deformities, and unfurling of the superior crus of the antihelix leading to a prominent ear all improved within a short treatment period.

In the current study, complications were limited to skin ulcerations in 3 percent of babies, which required application of bacitracin or no treatment. Over the course of the study, we found that pressure sores could be avoided in many cases by changing technique. It is necessary to reduce pressure on the conchal former by closing the lid less tightly and ensuring that the retractor is not directly overlying the posterior strut. It is also imperative to closely observe these children by examining them weekly. Despite these complications, none of the parents believed that their child was uncomfortable throughout the process, and 99 percent of the parents stated that they would repeat the procedure.

Many pediatricians fear telling a parent that there is a cosmetic concern about their healthy newborn baby, particularly during such a joyous time. Through this study, we found that 75 percent of the parents noticed the deformity before their pediatrician and that most parents jointly decided to attempt correction. Parents found the procedure simple. They noted that it did not

interfere with breastfeeding, irritate the baby, or cause negative public attention.

By avoiding otoplasty, children are not only escaping potentially serious complications, they are also circumventing years of psychological harm. Seventy-two percent of parents surveyed reported that they believed that the deformity would ultimately cause severe psychological harm to their child, which may be partially because of an increased awareness in the media of children being bullied in schools because of their deformities. This heightened awareness has a scientific foundation; studies have demonstrated that individuals with minor deformities experienced greater psychological torment than those with more severe facial deformities, and that surgical correction of ear deformities enhances self-confidence, increases social experience, and reduces bullying.^{1,2,19}

CONCLUSIONS

The molding period can be reduced from 6 to 8 weeks to 2 weeks by initiating molding during the first weeks of life and using a more secure and rigid device. Through an interdisciplinary approach, we were able to identify patients with ear deformities in the newborn nursery, correcting the deformity earlier and faster than has been previously published. Pediatricians and other health care professionals involved in the care of infants should be aware of this noninvasive, practical, and reliable technique, which has the potential to prevent future surgical intervention and psychological trauma.

Melissa A. Doft, M.D.

755 Park Avenue

New York, N.Y. 10021

md@doftplasticsurgery.com

REFERENCES

1. Bradbury ET, Hewison J, Timmons MJ. Psychological and social outcome of prominent ear correction in children. *Br J Plast Surg*. 1992;45:97–100.
2. Horlock N, Vögelin E, Bradbury ET, Grobbelaar AO, Gault DT. Psychosocial outcome of patients after ear reconstruction: A retrospective study of 62 patients. *Ann Plast Surg*. 2005;54:517–524.
3. Byrd HS, Langevin CJ, Ghidoni LA. Ear molding in newborn infants with auricular deformities. *Plast Reconstr Surg*. 2010;126:1191–1200.
4. Leonardi A, Bianca C, Basile E, et al. Neonatal molding in deformational auricular anomalies. *Eur Rev Med Pharmacol Sci*. 2012;16:1554–1558.
5. Tan ST, Abramson DL, MacDonald DM, Mulliken JB. Molding therapy for infants with deformational auricular anomalies. *Ann Plast Surg*. 1997;38:263–268.
6. Zambudio G, Guirao MJ, Sánchez JM, Girón O, Ruiz JJ, Gutiérrez MA. Nonsurgical correction of congenital auricular deformities: A new method of neonatal molding and splinting (in Spanish). *Cir Pediatr*. 2007;20:139–142.
7. Yotsuyanagi T, Yokoi K, Urushidate S, Sawada Y. Nonsurgical correction of congenital auricular deformities in children older than early neonates. *Plast Reconstr Surg*. 1998;101:907–914.
8. van Wijk MP, Breugem CC, Kon M. Non-surgical correction of congenital deformities of the auricle: A systematic review of the literature. *J Plast Reconstr Aesthet Surg*. 2009;62:727–736.
9. Ullmann Y, Blazer S, Ramon Y, Blumenfeld I, Peled IJ. Early nonsurgical correction of congenital auricular deformities. *Plast Reconstr Surg*. 2002;109:907–913; discussion 914.
10. Matsuo K, Hirose T, Tomono T, et al. Nonsurgical correction of congenital auricular deformities in the early neonate: A preliminary report. *Plast Reconstr Surg*. 1984;73:38–51.
11. Kurozumi N, Ono S, Ishida H. Non-surgical correction of a congenital lop ear deformity by splinting with Reston foam. *Br J Plast Surg*. 1982;35:181–182.
12. Nakajima T, Yoshimura Y, Kami T. Surgical and conservative repair of Stahl's ear. *Aesthetic Plast Surg*. 1984;8:101–107.
13. Smith W, Toye J, Reid A, Smith R. Nonsurgical correction of congenital ear abnormalities in the newborn: Case series. *Paediatr Child Health*. 2005;10:327–331.
14. Muraoka M, Nakai Y, Ohashi Y, Sasaki T, Maruoka K, Furukawa M. Tape attachment therapy for correction of congenital malformations of the auricle: Clinical and experimental studies. *Laryngoscope*. 1985;95:167–176.
15. Hall A, Ahmed T, Mehta D, Daya H. Customised ear moulds: A viable alternative to cosmetic ear surgery. *Arch Dis Child*. 2012;97:335.
16. Kubba H, Swan IR, Gatehouse S. The Glasgow Children's Benefit Inventory: A new instrument for assessing health-related benefit after an intervention. *Ann Otol Rhinol Laryngol*. 2004;113:980–986.
17. Raat H, Landgraf JM, Oostenbrink R, Moll HA, Essink-Bot ML. Reliability and validity of the Infant and Toddler Quality of Life Questionnaire (ITQOL) in a general population and respiratory disease sample. *Qual Life Res*. 2007;16:445–460.
18. Merlob P, Eshel Y, Mor N. Splinting therapy for congenital auricular deformities with the use of soft material. *J Perinatol*. 1995;15:293–296.
19. Tan KH. Long-term survey of prominent ear surgery: A comparison of two methods. *Br J Plast Surg*. 1986;39:270–273.