

Effectiveness Of Ear Molding In the Treatment Of Congenital Auricular Deformity

Corresponding authors:

CHEN Peiwei 1 LI Jie 2 ZHAO Shouqin 1 YANG Jingsong 1 DOU Jingmin 1 WEI Chenyi 1

Abstract

Objective: To evaluate the short-term efficacy of ear molding in the treatment of congenital auricular deformity.

Methods: 24 infants (28 ears) were treated with ear molding device (EarWell Infant Ear Correction System). Doctors and parents were surveyed 1 month after treatment.

Results: All cases were treated successfully without severe complications. 25 ears (89%) and 26 ears (92%) were rated as very satisfied or satisfied by doctors and parents, respectively.

Conclusion: Ear molding is a noninvasive treatment, and effectively corrects congenital auricular deformity.

Key words: Ear Disease; Deformity; Retrospective Study; Ear Molding.

INFORMATION

Auricular deformities are classified into structural malformation and morphological malformation^[1]. The former usually refers to the hypoplasia of the auricle caused by the coloboma of skin and cartilage. The latter is the abnormal morphology of the well-developed auricle, which could cause negative effects to the psychological development and social activities of children. Unlike structural malformations, such as microtia, which must be corrected by auricle reconstruction, the auricle deformity can be reconstructed either by surgery or by ear molding. At present in China, surgical plastic surgery treatment is the mainstream. We use EarWell ear molding to treat neonatal auricle deformity and achieve positive results.

MATERIALS AND METHODS

Clinical Materials

Patients with congenital auricular deformity who were treated with EarWell ear molding in our department from September 2016 to December 2016.

Inclusion Criteria

Age 2 weeks to 3 months; diagnosed as auricular morphological deformity by clinicians from otolaryngology department; observed for 2 weeks after birth, abnormal auricle without self-correction; no abnormal performance in newborn hearing screening test.

Exclusion Criteria

Age over 3 months; premature delivery; weight less than 2.5 kg; pathological jaundice, pneumonia and other systemic diseases.

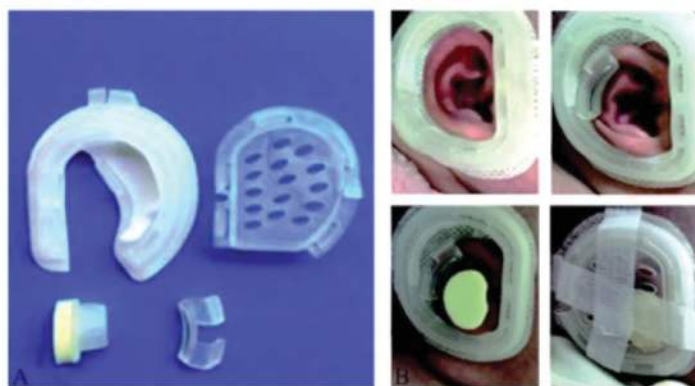
Overall 24 sick children (28 ears) were recruited for this treatment, including 14 males, 10 females, 16 right ears and 12 left ears. The age range for the recruited patients is 17-77 days, with a median age of 40.5 days.

Treatment Process

According to the size of the child's auricle and child's age, choose the right model of ear molding and wear it properly. The EarWell ear molding consists of four parts: Base, outer cover, retractor, and orthosis for cavity of concha (Figure 1). The base is attached to the skin through the bottom tape, fixing behind the ear to provide support for the bracket to correct the deformed helix, especially the shape of the helix. The retractor and the orthosis for cavity of concha need to be installed according to the deformity condition of the child to achieve an orthopedic effect. Note that the two parts should not be placed overlapping the base bulge to avoid over-pressure.



Figure 1
EarWell Ear Molding.



A: 4 PARTS

B: INSTALLATION PROCESS.

The retractor is placed on the deformed helix providing a continuous external force to make the helix regain a normal bending and reshape the navicular. The orthosis for cavity of concha is used to correct the abnormal protrusion of cavity of concha.

It should be placed in the cavity of concha according to the depth of external auditory canal and cavity of concha. The outer cover should be applied accurately aligned with the base, and the outer cover provides a continuous, external pressure for the retractor and the orthosis for cavity of concha to achieve an orthopedic effect. Finally, the surface of the outer cover should be covered and fixed with a medical tape.

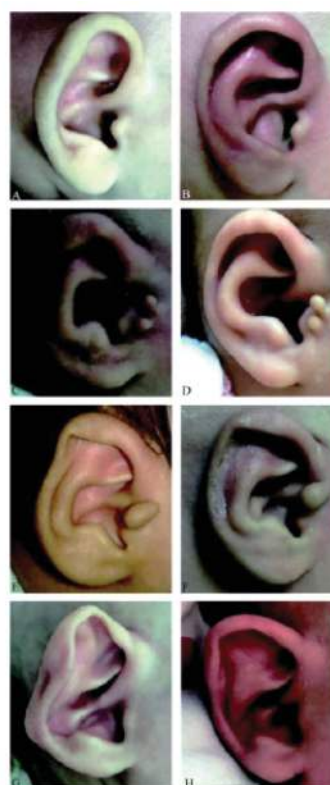The treatment time lasted for more than 2 weeks according to the condition of deformity. The EarWell ear molding was reviewed every week during the wearing period. Adjust the position of the ear molding according to the improvement of the auricle deformity. After the satisfying result of auricle orthosis was obtained, the patients should continue to wear it for 2 weeks and then end the treatment. If the corrective effect was not satisfactory, and no improvement was made for 3 consecutive weeks, the treatment was terminated. During the wearing period, it is necessary to ensure that the orthodontic device is fixed in the accurate position. If there is any complication such as skin ulceration, the orthotic device should be temporarily removed to wait for the ulcer to heal. Then reinstall the device, and extend the treatment time appropriately. The auricles were taken pictures before and after treatment to compare the orthopedic effect. One month after the treatment, the orthopedic effects were evaluated by the physician and the parents respectively. The evaluation grade is divided into: Very Satisfied (the deformed auricle is corrected); Satisfactory (the deformed auricle is corrected, basically recovered to the appearance of the normal auricle structure, but slightly different from the healthy ear); Slightly Improved (the deformed auricle is partially improved, but failed to return to the normal auricle structure); and Invalid (the deformity of the auricle correction is not obvious, or not improved). No complications are recorded to happen during the treatment.

RESULTS

All 24 children (28 ears) successfully completed the treatment, including 9 protruding ears/cup ear, 6 lop-ear, 7 ring ears, 2 constricted ears, 2 Stahl's ears, 2 cryptotia, and 2 ears with complex deformities. The average duration of treatment was 21.5 days. All ear deformity was improved to different degrees (Figure 2). Physician's evaluation 2 months after the end of treatment: Very satisfied with 14 ears, satisfied with 11 ears, slightly improved 3 ears, invalid 0 ears. Parents' evaluation: Very satisfied with 17 ears, satisfied with 9 ears, slightly improved 2 ears, invalid 0 ears (Table 1). We take the evaluation result of very satisfied and satisfied as effective intervention, the total effective rate was 89% (physician's evaluation) and 93% (parents' evaluation). One ear out of 28 ears had skin ulceration. The wound healed and the patient re-wore the ear molding to continue treatment after removing it for 3 days. Another

ear had rash near the place that tape directly attached to the skin, but the rash was relieved after the treatment and no serious complications occurred.

Figure 2
Therapeutic effect of EarWell ear molding.



PROTRUDING/CUP EARS

A: Before treatment: Disappeared antihelix and navicular fossa, skull-auricles angle 60°.

B: After treatment: Reappearance of antihelix, navicular fossa, skull-auricles angle < 30°.

LOP-EAR

C: Before treatment: The lower part of the helix was folded covering part of the navicular fossa.

D: After treatment: The shape of the auricle was restored.

CONSTRICTED EAR

E: Before treatment: Partial auricle and contractile auricle were close to each other, and navicular fossa disappeared.

F: After treatment: The shape of the auricle and navicular fossa return normal.

COMPOUND DEFORMITY

G: Before treatment: Coexisting of protruding ear, constricted ear, Stahl's ear and Conchal crus.

H: After treatment.

DISCUSSION

The rate of neonatal auricular deformity reported by China is 43.36% [3], less than the rate of 55.2% similarly reported by the foreign world [4]. 5-9 weeks of pregnancy is the development time window for auricular cartilage bracket. During this time period, abnormal embryonic development could cause the structural coloboma of auricle cartilage and soft tissue, which leads to structural deformity of auricle cartilage. The morphological deformity always develop 9 weeks after pregnancy, due to intrauterine or postpartum improper physical external force causing deform of the auricle bracket [5], including birth canal compression, fetal position, improper sleeping position, etc. Among these deformities, helix and the antihelix are the most common parts that could be affected by the physical external pressure.

Morphological malformation can be subdivided into various subtypes:

1) Protruding ears: The auricle is excessively forward, the angle of the ear is approximately 90°; 2) Cup ear: The antihelix and the triangular fossa are deep-sunken, resembling the shape of a wine glass; 3) Lop-ear: The helix folds downward to cover the antihelix and/or the navicular; 4) Stahl's ear: Abnormal cartilage protrusion between the upper crus of antihelix and the helix; 5) Deformity of the helix: The helix loses its original curved shape and becomes flat, or even disappeared; 6) Conchal crus: The crus of the helix is abnormally protruding in the cavum conchae, and can be extended to the antihelix; 7) Ring ear: The helix

and the antihelix stick to each other, the periotic issue disappears; 8) Ear with compound deformity: Different auricular deformities exist simultaneously; 9) Cryptotia: The upper part of the auricle is buried under the scalp of the tempora, and there is no obvious retro auricular groove. Cup ear is always combined with protruding ear, which is the most common type of morphological malformation. We combined the cup ear or the protruding ear and the auricular co-existing these two types of deformity, and classified them together as protruding/cup ear. In this study, the protruding/cup ear and the lop ear were the majority, which was consistent with foreign reports [6].

Auricular malformation does not endanger the patient's life, but when the patient realizes his auricle deformity then the patient is prone to have anxiety, inferiority, paralysis, suspicion, nervousness, solitude, depression and other psychological disorders, leading to abnormal social activities and seriously affecting children's physical and mental health development [7]; another survey showed that personality disorder increased significantly with age [8]. Hence the auricular deformities should be intervened as early as possible to prevent psychological disorders. Auricular structural deformity must be corrected by auricular reconstruction surgery, such as microtia [9]; but for the morphological deformity of auricle, 30% deformed auricle can be self-corrected within 2 weeks [6,10], the other auricles that failed to self-correct to the normal shape need to be corrected by auricular plastic surgery [2]. Through suturing, transferring skin flap, cartilage resection and other surgical techniques, the auricle obtains a near-normal shape. Such surgery requires children to be at least 6 years old, and the auricle develops to the size as large as 90 % of the size of adult's auricle [11]. Most of the children were aware of their auricular deformities before the age of 6 and hence developed some psychological disorders. Additionally, there were various complications of the surgery. It was reported that the incidence of complications, such as hematoma and infection, happened in early post-surgery stage was 5%. While the incidence of some late post-surgery stage complications, such as pain, fistula, cheloid, and recurrence of deformities can reach 20% [12]. In recent years, ear mold correction has been used as a non-surgical treatment for neonatal auricular malformation and has achieved good results.

Table 1
Clinical Data for the 24 patients (28 ears) with auricular deformities.

Number/Gender/Age (days)/Side/Treat time (days)/Category
/Physician's evaluation/Parent's evaluation/Complications

表1 24例(28耳)耳部畸形患儿临床资料									
编号	性别	年龄(d)	侧别	治疗时间(d)	类型	医师评价	家长评价	并发症	
1	男	50	右	14	垂耳	满意	很满意	无	
2	女	40	右	16	垂耳	很满意	很满意	无	
3	男	46	右	14	环隙耳	很满意	满意	无	
4	女	60	左	14	垂耳	很满意	很满意	无	
5	男	43	左	21	环隙耳	满意	满意	无	
6	男	49	左	21	招风耳-杯状耳	满意	满意	无	
7	男	65	右	28	复合畸形	稍改善	满意	无	
			左	35	复合畸形	稍改善	稍改善	皮肤破溃	
8	女	20	右	17	招风耳-杯状耳	满意	很满意	无	
9	女	58	左	11	招风耳-杯状耳	很满意	很满意	无	
10	男	17	右	21	环隙耳	很满意	满意	无	
11	男	35	左	14	招风耳-杯状耳	满意	很满意	无	
12	女	41	左	28	招风耳-杯状耳	很满意	很满意	无	
13	男	28	右	19	环隙耳	满意	很满意	无	
14	女	39	右	12	垂耳	很满意	很满意	无	
15	男	77	左	14	招风耳-杯状耳	很满意	很满意	无	
16	女	53	右	19	垂耳	满意	满意	无	
17	男	42	右	14	环隙耳	很满意	很满意	无	
18	男	39	右	26	招风耳-杯状耳	很满意	满意	无	
19	男	34	右	28	隐耳	满意	很满意	皮肤	
20	女	16	右	19	招风耳-杯状耳	很满意	很满意	无	
			左	19	招风耳-杯状耳	很满意	很满意	无	
21	女	23	右	28	隐耳	很满意	很满意	无	
22	男	29	右	30	Stahl耳	满意	满意	无	
			左	30	Stahl耳	满意	很满意	无	
23	男	24	左	21	垂耳	很满意	很满意	无	
24	女	47	右	28	环隙耳	满意	满意	无	
			左	42	环隙耳	稍改善	稍改善	无	

Maternal estrogen remains in the neonatal blood circulation, and it peaks within 72 hours after birth, maintaining the high plasticity of the neonatal auricle by increasing the hyaluronic acid concentration in the cartilage [13]. Based on this theory, due to the strong plasticity of auricle during the neonatal period, the deformed auricle could be corrected to normal shape by wearing ear molding. EarWell ear molding aligner is developed abroad and it is clinically proven to be a simple, non-invasive, efficient and low-cost treatment, which is more effective than traditional surgery. Different types of auricular morphological deformity could be corrected up to 90% [6,11,13,14]. In the past, EarWell ear molding is taken for uncertain in the treatment of cryptic ear [6,10], but in recent years' clinical application, it has confirmed satisfactory orthopedic effects on treating cryptic ears [14].

The total effective rate of this study is 90%, which proves that EarWell ear molding is efficient, and both foreign reports and us have found that the most common complication of the treatment is skin ulceration, which is easy to treat and has low incidence. While the hematoma, cartilage necrosis, etc. are comparatively rare as complications. The use of EarWell ear molding avoids serious complications of plastic surgery and there is no need for general anesthesia, which is more acceptable for most parents. Lop ear, Stahl's ear and other morphological malformation of the upper 1/3 auricle can be corrected by the ear molding within only 3 months of the newborn. For the cryptotia, if the cartilage structure of the deformed ear itself is intact, then the deformity could be corrected and improved by wearing ear molding within 6 months after birth, according to some reports [4]. The maternal estrogen of newborns continues to decline after the postpartum peak. Although breastfeeding could theoretically delay the decline process, after 6 weeks, estrogen drops to the baseline level [13], meanwhile the plasticity of the auricle gradually weakens. Hence, for the better treatment outcome, it is vital for the newborns to have the treatment as soon as possible.

Tan, et al, [1] believed that the ideal orthopedic effect could be reached if the newborn accepted the treatment within 3 months after birth, but the curative effect was closely related to the starting time of the treatment. Byrd, et al, [5] reported that if the treatment began more than 3 weeks after birth, the patient needs to extend the wearing time and the curative effect is halved. Tan, et al, [1] reported that 5 ineffective treatment cases all started treatment 3 months after birth. Therefore, early treatment is advocated, which is beneficial to obtain better curative effect and shorten treatment time. In recent years, many reports have shown that the treatment time is 3 days to 3 months [6,10,11,13-15]. Some others believe that the treatment time should be advanced, even strictly set on the day of birth or within 3 days after birth [15] to improve overall cure rate. In our treatment, considering that 30% of the newborn's auricular morphological deformity can be corrected by itself within 2 weeks and the domestic ear molding is still in its early stage, additionally, there is no domestic efficacy report, we set the treatment time window for this study to 2 weeks to 3 months. During the 2 weeks after birth, we observe whether the deformed auricle has self-correcting improvement. If there is no improvement, we will apply the EarWell ear molding to the patient. Newborns aged more than 3 months have not been included in the treatment because of the previously reported poor treatment efficacy. The initial treatment age of the 24 children was 17-77 days, and the auricular morphological abnormalities of the children were improved to different degrees. The observation period before treatment may not have a great impact on the treatment effect, but limited by the sample size, it cannot reflect the difference in treatment efficacy among different starting times.

There is no unified standard for the duration of treatment of EarWell ear molding. At present, most experts adjust the treatment time according to the orthopedic effect during the follow-up observations [6, 14, 16, 17]. Those with poorer corrective effect often obtained potential improvement and better result by prolonging the treatment time. In this study, there are 3 ears that received the physician's evaluation of slightly improved, and the treatment time duration of these 3 ears were the longest in all cases. Doft, et al, [14] reported an average orthopedic time of 158 ears for 2 weeks, while Mohnmadi, et al, [16] reported that 21 cases of mean correction lasted for 13 weeks, and the effective rate was only 57.14%, much lower than Doft's 96%. However, it is notable that Doft's case were treated within 2 weeks after birth, while Mohnmadi's average starting treatment time was 7 weeks. The duration of treatment is closely related to the age at which treatment begins. The auricular morphological deformities that are treated early are more likely to achieve satisfactory orthopedic effects, and the treatment duration is shorter.

Additionally, the duration of treatment may vary according to the treatment plan of each center. Woo, et al, [17] reported that the average treatment duration in their study was 33 days in 18 cases (28 ears), compared to our study of 21.5 days. The age structure of these two studies was similar to each other. However, Woo, et al, set up follow-up interviews every 2 weeks and continued the treatment for 2 weeks after obtaining orthopedic effects, while our study set both follow-up interval and continuous treatment time to 1 week. Although our study lacks long-term follow-up, it has been reported that the ear molding treatment can maintain the effect and even further improve it one year after the orthopedic effect is obtained [14, 17]. No auricular deformity rebound was found in all cases.

The clinical effect of EarWell ear molding is satisfying, but even in foreign countries, the reason why this treatment is still not well accepted and conducted [6, 14, 15], firstly because the wrong concept of "congenital auricular deformities can usually self-heal with growth and development" usually delays the time of treatment. Secondly, the treatment of auricular deformity is generally performed by an otolaryngology or orthopedic surgeon, while obstetricians and neonatologists are lack of comprehensive knowledge of this disease and the missed diagnosis of deformity could be easily made. Compared to the foreign countries, the domestic situation is more severe. At present, this treatment is only conducted in a very small area. Although the self-correcting rate is 30%, there is no examination that can distinguish the self-correcting ability of the deformed auricle. If there is no improvement of the auricle within 2 weeks, then it would be considered as no self-healing tendency.

Applying the EarWell ear molding to the deformed auricle with no self-correcting tendency within 2 weeks after birth not only avoids auricular plastic surgery, but also avoids possible intra-ocular complications. Besides, it can also correct the deformities in neonatal period before the patient has awareness of the deformities. Hence, it is more likely to avoid the patient to develop further psychological barriers. Foreign data has shown that after providing relevant treatment data, 99% of parents choose ear molding treatment without hesitation in 30% and 90% of the choices [14]. Therefore, to promote the ear molding treatment, it is necessary to strengthen the education of auricle deformity-related hazards, deepen the parents' and physicians' cognition of the deformity, and arise considerable attention to this disease. At present, the ear molding is designed based on the data measured from the auricles of foreign children, and there is no model for domestic newborns,

neither has any database of neonatal auricle morphology in China [3]. Lack of data greatly limited the prospect of accurate treatment in China, but according to our experience, the application of the current EarWell ear molding can also achieve satisfactory results, which may indicate that there is no significant difference in the auricle morphology for domestic and oversea newborns.

Auricular morphological deformities require early intervention. As a non-invasive treatment, EarWell ear molding has a significant effect on the treatment of neonatal auricle morphological deformities. All forms of auricle morphological deformities including cryptotia are considered to be the indications of this treatment. Hopefully this treatment could be promoted as the first-line treatment for most newborn auricle deformities.

REFERENCES

- [1] Tan, S.T.; Abramson, D.L.; MacDonald, D. M.; et al. *Molding Therapy For Infants With Deformational Auricular Anomalies*. Ann Plast Surg, 1997; 38 (3): 263-268.
- [2] 毕晔, 林琳, 宋宇鹏, 等. 先天性复合耳廓畸形的类型与临床治疗. 中华耳科学杂志, 2013; (4): 481-484.
- [3] 吴胜林, 齐向东, 赵卉, 等. 新生儿耳廓形态学分型的初步研究. 中国临床解剖学杂志, 2013; 31 (4): 384-388.
- [4] Matsuo, K.; Hayashi, R.; Kiyono, M.; et al. *Non-Surgical Correction Of Congenital Auricular Deformities*. Clin Plast Surg, 1990; 17 (2): 383-395.
- [5] Porter, C.J.; Tan, S.T. *Congenital Auricular Anomalies: Topographic Anatomy, Embryology, Classification and Treatment Strategies*. Plast Reconstr Surg, 2005; 115 (6): 1701-1712.
- [6] Byrd, H.S.; Langevin, C.J.; Ghidoni, L.A. *Ear Molding In Newborn Infants With Auricular Deformities*. Plast Reconstr Surg, 2010; 126 (4): 1191-1200.
- [7] Horlock, N.; Vogelin, E.; Bradbury, E.T.; et al. *Psychosocial Outcome Of Patients After Ear Reconstruction: A Retrospective Study Of 62* [不完整].