

# Ear Molding in Newborn Infants with Auricular Deformities

H. Steve Byrd, M.D.  
Claude-Jean Langevin,

M.D., D.M.D.

Lorraine A. Ghidoni, M.D.

Dallas, Texas



**Background:** A review of a single physician's experience in managing over 831 infant ear deformities (488 patients) is presented.

**Methods:** The authors' methods of molding have advanced from the use of various tapes, glues, and stents, to a comprehensive yet simple system that shapes the antihelix, the triangular fossa, the helical rim, and the overly prominent conchal-mastoid angle (EarWell Infant Ear Correction System).

**Results:** The types of deformities managed, and their relative occurrence, are as follows: (1) prominent/cup ear, 373 ears (45 percent); (2) lidding/lop ear, 224 ears (27 percent); (3) mixed ear deformities, 83 ears (10 percent) (all had associated conchal crus); (4) Stahl's ear, 66 ears (8 percent); (5) helical rim abnormalities, 58 ears (7 percent); (6) conchal crus, 25 ears (3 percent); and (7) cryptotia, two ears (0.2 percent). Bilateral deformities were present in 340 patients (70 percent), with unilateral deformities in 148 patients (30 percent). Fifty-eight infant ears (34 patients) were treated using the final version of the EarWell Infant Ear Correction System with a success rate exceeding 90 percent (good to excellent results). The system was found to be most successful when begun in the first week of the infant's life. When molding was initiated after 3 weeks from birth, only approximately half of the infants had a good response.

**Conclusions:** Congenital ear deformities are common and only approximately 30 percent self-correct. These deformities can be corrected by initiating appropriate molding in the first week of life. Neonatal molding reduces the need for surgical correction with results that often exceed what can be achieved with the surgical alternative. (*Plast. Reconstr. Surg.* 126: 1191, 2010.)

Infant auricular deformities are classified either as malformation or deformation. Malformations are characterized by a partial absence of the skin or cartilage resulting in a constricted or underdeveloped pinna, whereas deformations are characterized by a misshaped but fully developed pinna.<sup>1</sup> Molding is best suited for deformations, but is useful in cases of less severe malformation.

Our first experience with ear molding was in 1989 with a unilateral Stahl's ear deformity. Evidence in the Japanese literature<sup>2-4</sup> showed promising results with ear molding at that time. Our technique then involved rather crude fabrication of helical rim stents from thermoplastic dental compound supported with Steri-Strips (3M, St.

Paul, Minn.) to hold the ear in place. This was maintained for approximately 4 weeks and produced an outcome with improved shape but

**Disclosures:** Dr. Byrd has a royalty agreement with Becon Medical for his work on the EarWell device; neither of the other authors has any commercial associations or financial disclosures that might pose or create a conflict of interest with information presented in this article. No funding was received for the work presented in this article.

From the Department of Plastic Surgery, University of Texas Southwestern Medical Center at Dallas; Children's Medical Center Dallas; and the Department of Pediatrics, Baylor University Medical Center.

Received for publication January 18, 2010; accepted March 22, 2010.

Copyright ©2010 by the American Society of Plastic Surgeons

DOI: 10.1097/PRS.0b013e3181e617bb

Supplemental digital content is available for this article. A direct URL citation appears in the printed text; simply type the URL address into any Web browser to access this content. A clickable link to the material is provided in the HTML text of this article on the *Journal's* Web site ([www.PRSJournal.com](http://www.PRSJournal.com)).

lacked the full aesthetic definition of a normal ear. We also quickly realized that when infants with deformity were seen after 3 weeks of age, molding had to be maintained for a very prolonged interval, often exceeding 3 months and requiring an inordinate time commitment from physician and parents. Sadly, only approximately half of the infants treated with late-onset molding, after 3 weeks of age, had good outcomes. As a result, we adopted rather restrictive policies for the use of ear molding. Infants seen at birth with auricular deformity were reevaluated at 5 to 7 days. If the deformity had not improved, ear molding was initiated. If the ears were assuming a normal shape, no treatment was offered. In a subgroup of infants who had some improvement, observation was continued into the second week, and ear molding was initiated if spontaneous correction was not observed by the end of the week. Over time, we realized that postponing molding to await spontaneous recovery only increased the likelihood of failure or poor outcome and increased the interval required for molding.

Parallel to these observations, virtually 100 percent of children and adults seen for otoplasty gave a history of the deformity being present since birth. This coupled with the seemingly universal teaching in pediatrics that these deformities would self-correct led to a study in a local nursery of 100 prospective births. Observations and photographs of all infant ears suspected of being abnormal were made by the attending pediatrician and nursing staff. Of the 100 infants, 39 were

noted to have misshapen ears. Of the 200 infant ears seen, 58 were deemed misshapen (29 percent). We estimate that approximately one-third of the misshapen ears present at birth self-correct in the first week, leaving 15 to 20 percent of newborns as candidates for molding.

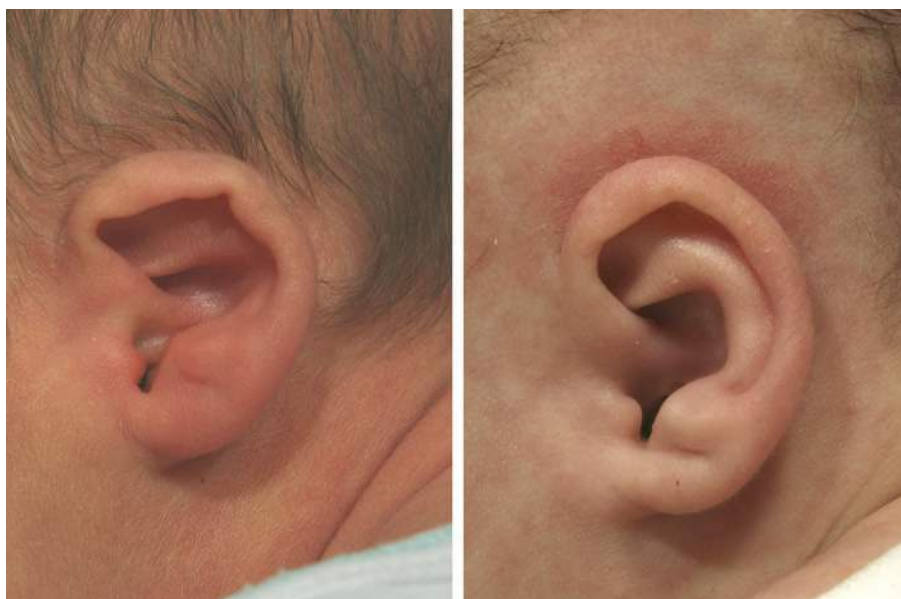
## PATIENTS AND METHODS

### Seven Patterns of Deformation

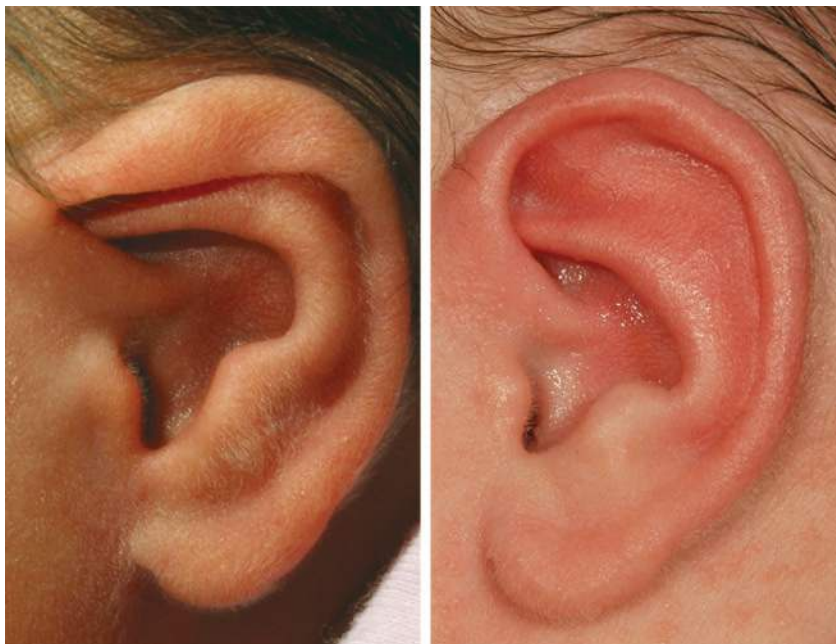
Prominent/cup ear may be secondary to a widened, conchal-mastoid angle, an absent antihelical fold, or a combination of both (Fig. 1, *left*). The prominent/cup ear deformity was the most common type and present in 373 ears (45 percent). The antihelical fold requires posterior stenting with anterior pressure to deepen the scapha, whereas the conchal-mastoid angle is only amenable to anteriorly directed forces.

Lidding/lop ear constitutes a folding over of the upper third of the ear and was present in 224 ears (27 percent) (Fig. 2, *left*). This may be limited to the helical rim (lidding) or complete folding over of the rim and scapha (lop ear). In this group, it is not only critical to fold the rim and ear back in position, but also to reconstruct the superior limb of the triangular fossa that represents a continuance of the antihelical fold out to the helical rim.

Mixed deformities comprise various combinations of ear deformities and often involve the presence of a conchal crus with prominent/cup ear



**Fig. 1.** Prominent/cup ear before (*left*) and after therapy (*right*).

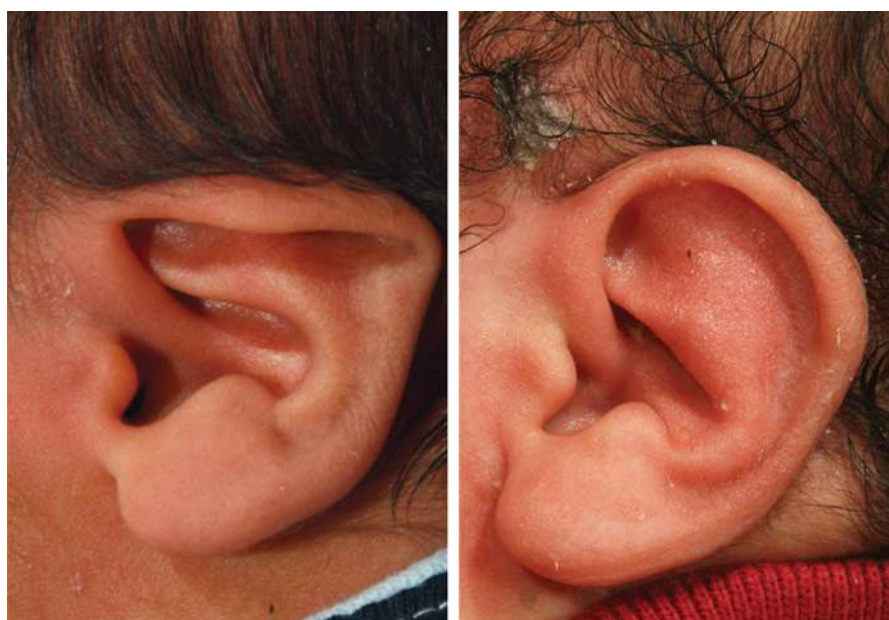

**Fig. 2.** Lidding/lop ear before (*left*) and after therapy (*right*).

(Fig. 3, *left*). Mixed deformities were seen in 83 ears (10 percent).

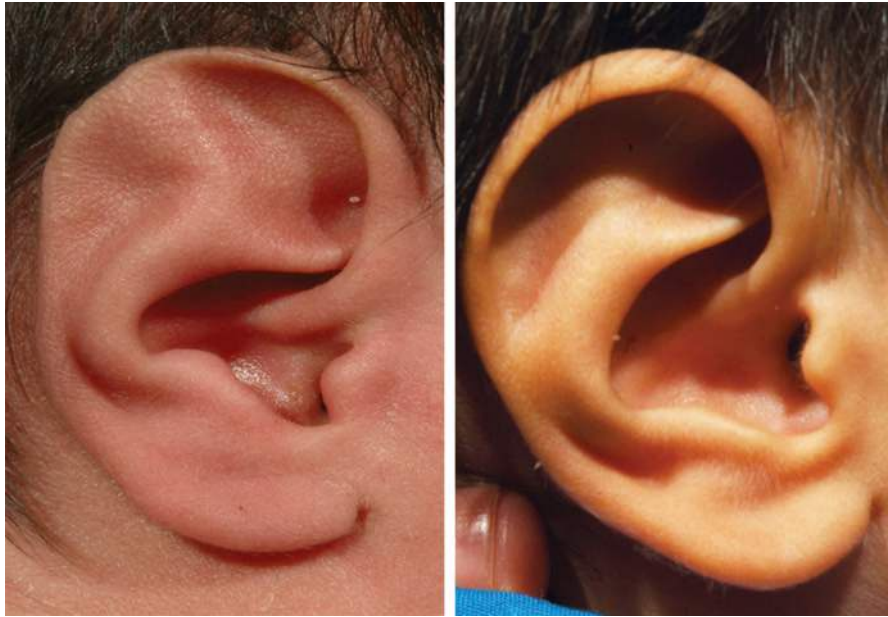The Stahl's (Spock) ear is also a deformity involving the upper third of the pinna and was present in 66 ears (8 percent) (Fig. 4, *left*). It is characterized by a transverse cartilaginous crus extending from the normal Y of the antihelical fold out to the helical rim. The normal superior limb of the triangular fossa is absent or deformed

by the presence of the transverse crus. The upper third of the helical rim may be flattened, failing to maintain the aesthetic curvature that is seen in the lower and mid thirds of the ear. The key to the correction of this deformity involves the creation of the normal, superior limb of the triangular fossa; obliteration of the abnormal, transverse crus; and reshaping of the helical rim and scapha.



**Fig. 3.** Mixed ear deformity before (*left*) and after therapy (*right*).



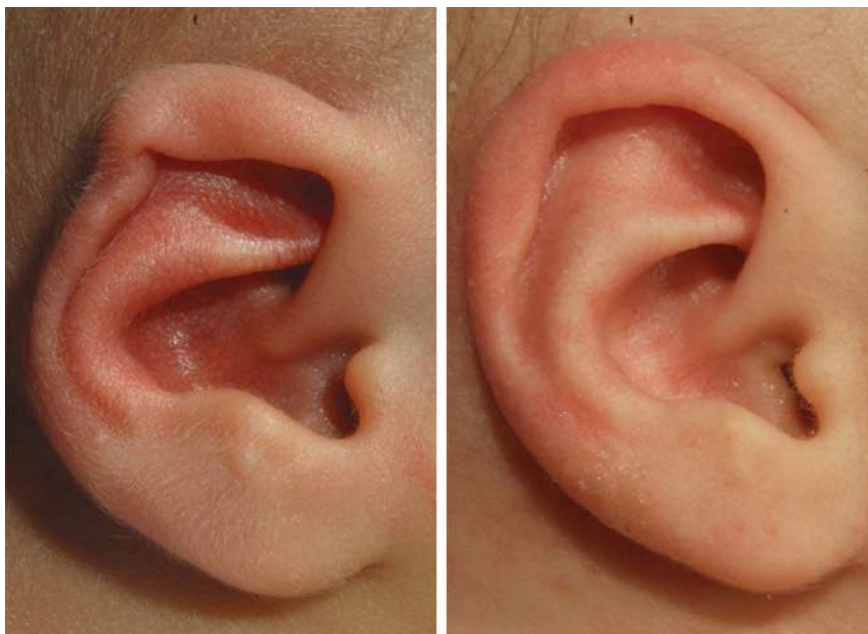


**Fig. 4.** Stahl's ear before (*left*) and after therapy (*right*).

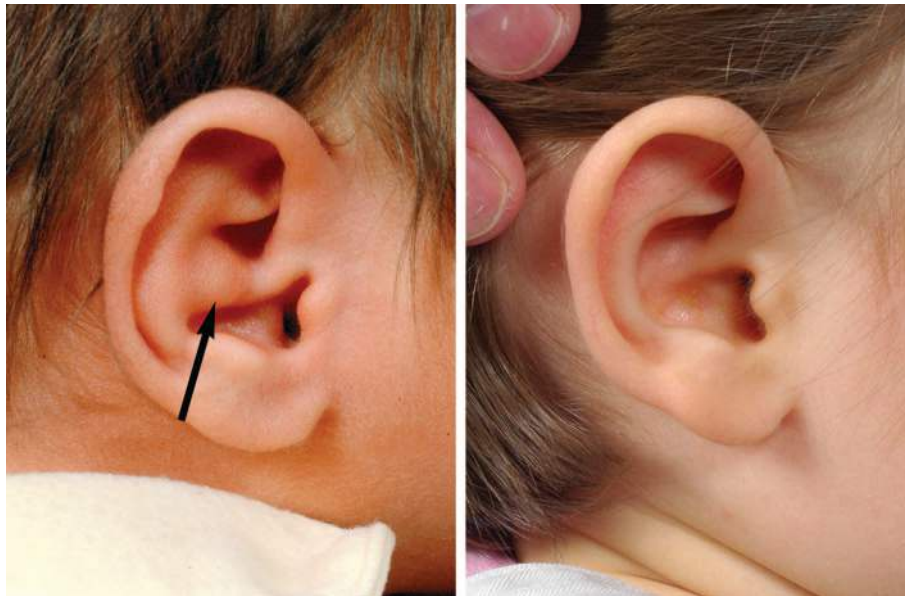
Helical rim deformities may present as an absent rim failing to have any curvature and just extending as a flattened appendage off the scapha (Fig. 5, *left*). The rim may be compressed so that it folds over, touching the lateral aspect of the antihelix and obliterating the scapha. When compressed, it must be distinguished from a Tanzer II constricted deformity where an actual skin and cartilage shortage is present. In addition, the rim

may be irregular or misshapen. Helical rim deformities were found in 58 ears (7 percent).

The conchal crus is a convex crus crossing the midportion (cymba conchae) and extending onto the vertical wall of the concha (Fig. 6, *left*). It was present in 25 ears (3 percent) as an isolated deformity but was present in all of the 83 ears with mixed deformities. The conchal crus frequently appears as a continuation of the helical rim across



**Fig. 5.** Helical rim deformity before (*left*) and after therapy (*right*).



**Fig. 6.** (Left) Conchal crus before therapy. The arrow points to the convex crus crossing the cymba conchae and extending onto the vertical wall of the concha. (Right) Postoperative appearance.

the concha and was referred to as a prolonged crus helicus by Matsuo et al.<sup>3</sup> Often, the conchal crus deformity is associated with prominent/cup ear. Like the conchal-mastoid angle, it requires anterior forces for correction.

The least common of the deformities among Caucasian, Hispanic, and African American infants seen in our nurseries was cryptotia, which was found in only two ears (0.2 percent). Cryptotia is characterized by the absence of a retroauricular skin sulcus, with the cartilage framework adherent to the skull. Its incidence is higher in the Japanese series and requires pinching and molding of skin to recreate the sulcus.

Of these deformities, the most difficult to diagnose is the normally shaped but prominent ear. These infants appear cute, and when the abnormality only involves the conchal-mastoid angle, the pinna itself is not deformed. In a separate and independent nursery study, 100 infants were measured for projection at the midpoint of their ear. The average projection of the helical rim from the mastoid was 5.3 mm, with a median projection of 5.0 mm and a mean deviation that did not exceed 1.7 mm. From these findings, we conclude that overprojection of the infant ear secondary to an increased conchal-mastoid angle should be suspected when projection exceeds 8.0 mm in the otherwise normal-appearing ear.

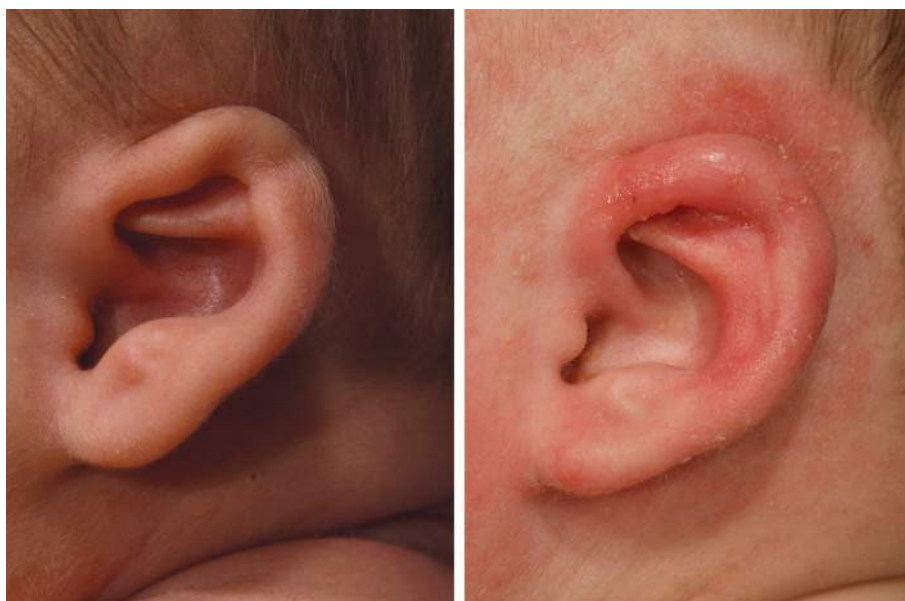The malformation most benefited by molding is the Tanzer II constricted ear. This malformation

affects the helical rim and scapha with varying degrees of skin and cartilage shortage (Fig. 7, left). The great challenge in the treatment is achieving true expansion of the skin and cartilage framework.

### Molding Forces to Correct Infant Ear Deformity

Birth deformities of the ear most frequently involve the upper one-third of the ear. Incomplete formation of the superior limb of the triangular fossa, which is a continuation of the antihelical fold, is almost always present. The absence or maldevelopment of this cartilaginous fold invariably leads to helical rim and scapha deformation. Accordingly, three key molding forces are necessary to correct these deformities:

1. There must be a stent or conformer resting along the retroauricular sulcus in direct alignment with the antihelix to create a continuation of the antihelical fold into the superior limb of the triangular fossa.
2. An anterior conformer, curved to match the natural curvature of the helical rim, places anteriorly directed forces in the scapha. This conformer should not overlap the posterior conformer to avoid pressure injury.
3. Helical rim retraction enables the helical rim to be expanded to its full dimension. In some cases, there is no helical rim development, so in addition to retraction, the heli-



**Fig. 7.** A Tanzer II constricted ear before (left) and after therapy (right).

cal rim itself must be created to provide the delicate cartilaginous arch that characterizes the rim.

### Midconchal Deformities

In reviewing infants who had poor outcome or failures in molding, almost all were limited to a recurrence of overprojection. Many of these ears were noted to have a conchal crus bisecting the midsection of the cymba conchae and extending onto the vertical wall of the concha. Sometimes, this crus was only seen when the pinna was pushed back to its normal position. The antihelical fold was well shaped; however, the conchal-mastoid angle was widened. Generally, this produced overprojection across the midportion of the ear but sometimes affected the upper third as well.

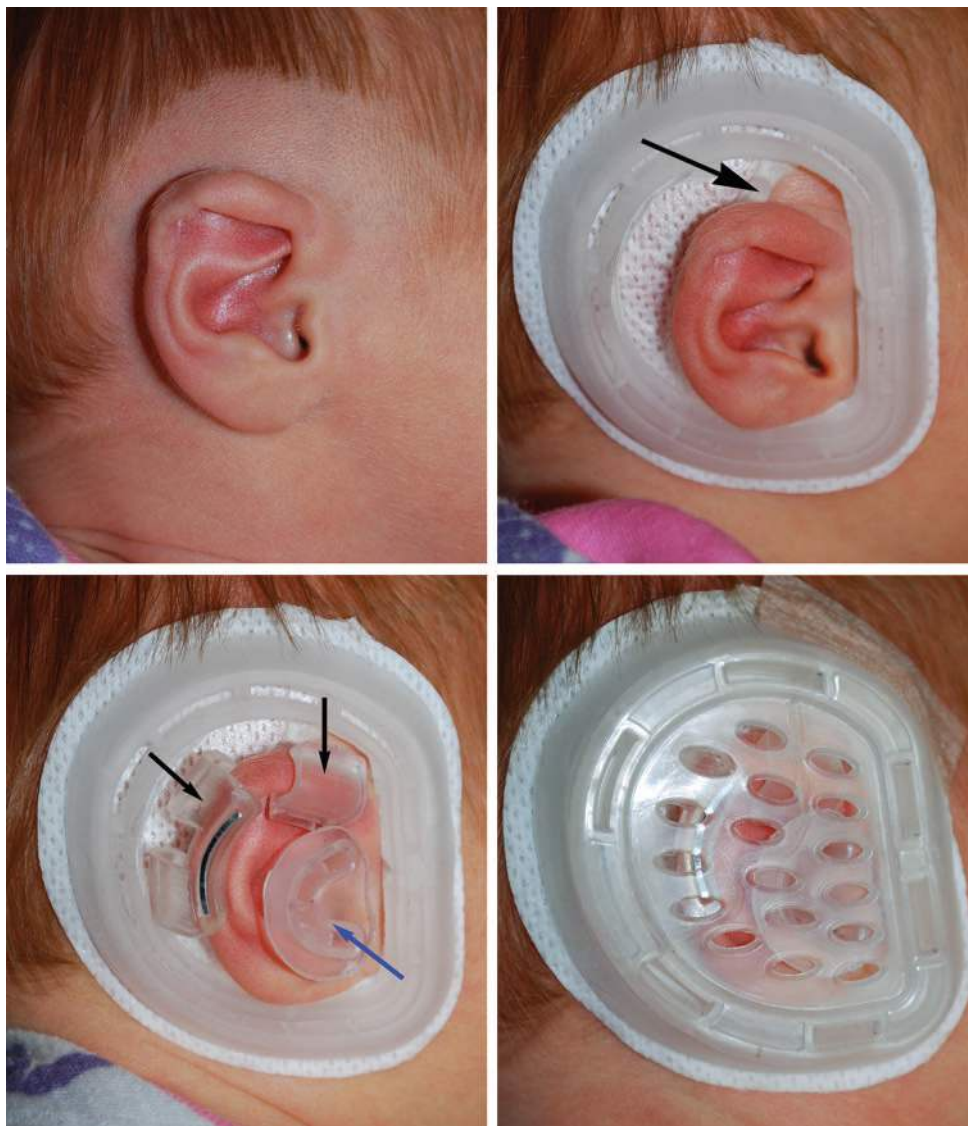A subset of children in this group had well-shaped and normal-projecting ears when molding was terminated at 6 weeks. However, over the course of 6 months, recurrent overprojection was seen. This overprojection was again most notable in the conchal-mastoid angle. These children were also unique in that they had a family history of prominent ear deformity. It may be that the genetic influence in these children extends well beyond the period of molding therapy and destines them to late recurrence. Attempts at taping molds in the conchal hollow to correct the conchal crus and conchal-mastoid angle were not successful. The inability to apply enough anterior force with taping and the consequent obliteration of the ex-

ternal auditory canal severely compromised any efforts at molding this area.

With evidence that the conchal crus was a factor in increasing the conchal-mastoid angle and producing a prominent ear deformity, we created a molding device that would allow correction of the upper third as previously described and, at the same time, allow anterior forces to be applied to the concha that would flatten the conchal crus and correct the conchal-mastoid angle. A nonocclusive hypoallergenic adhesive was required to hold for a prolonged interval the device to an infant's ear without damaging the skin.

The final result incorporating all of these requirements was a two-piece cradle system that slipped over the pinna and attached to the skin surrounding the ear. The posterior cradle incorporated a posterior conformer that guided the fold of the antihelix into the superior limb of the triangular fossa while providing an adhesive surface to hold the device against the scalp. A retractor system was subsequently developed to shape and hold the helical rim in position. The retractor was designed so that the helical rim snapped into its preshaped arched cavity and the adjustable rim of the retractor served as an anterior stent to the scapha. The retractor then attached to the inner adhesive surface of the posterior cradle, allowing retraction and expansion of the rim and scapha when indicated. A soft compressible conchal former was designed with an opening toward the external auditory canal and was made to fit in the





**Fig. 8.** The EarWell Infant Ear Correction System. (Above, left) Infant with Stahl's ear deformity. The scalp hair is shaved approximately 2 cm around the ear and prepared with alcohol to create a hairless footprint to facilitate adherence of the posterior cradle against the scalp. (Above, right) The posterior cradle is placed, making sure to orient the posterior conformer into the antihelix and the future proposed superior limb of the triangular fossa. The *arrow* points to the posterior conformer. Note the improvement in the helical rim deformity by the placement of the posterior guide. (Below, left) Placement of the retractor system to shape and hold the helical rim in position (*black arrows*). These retractors are held in place by the inner adhesive surface of the posterior cradle. A soft compressible conchal former is placed within the conchal cavity (*blue arrow*). The height of this device can be augmented by the addition of compressible foam to its surface. (Below, right) The clear and perforated anterior shell attaches to the posterior cradle, allowing direct anterior forces to be applied to the conchal former and retractor system.

conchal cavity. The wall of the conchal former was created to rest against the vertical wall of the concha so that it would exert a downward force at the takeoff of the concha from the skull (conchal-mastoid angle). The height of the conchal former

can be varied by the addition of compressible foam to its surface.

The anterior shell was attached to the posterior cradle, allowing direct anterior forces to be applied to the conchal former and retractor system. By mak-

ing the construct of the cradle clear and with perforations, moisture collection was minimized and direct visualization of the skin was permitted. The adhesive of the device lasts approximately 2 weeks, requiring two additional applications for a total treatment period of 6 weeks. A universal size EarWell device (EarWell Infant Ear Correction System; Becon Medical Ltd., Tucson, Ariz.) was created for babies whose weight ranged from 4.5 to 8 pounds, and a second, larger sized version was fashioned for large-ear infants weighing more than 8 pounds. Fifty-eight infants ears (34 patients) were treated with the final version of the EarWell System (Fig. 8). (See Video, Supplemental Digital Content 1, which demonstrates the use of the EarWell System, <http://links.lww.com/PRS/A202>).

## RESULTS

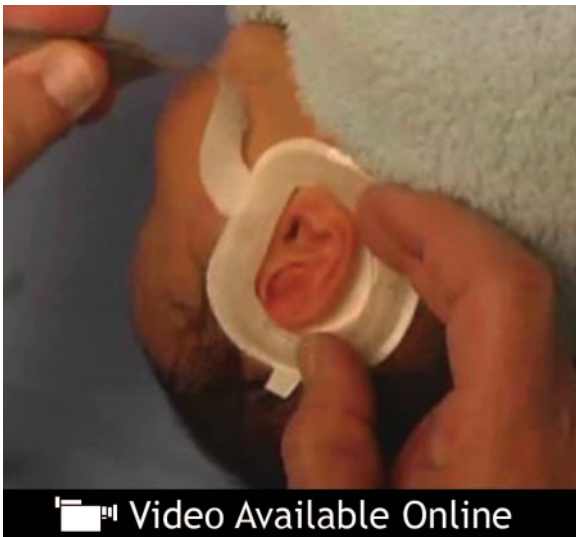Final auricular morphologic results were classified as excellent (normal shape), good (near normal shape with some degree of abnormality), and poor (slight or no improvement). From the final construct of the EarWell Infant Ear Correction System, 58 infant ears (34 patients) have been managed with a success rate exceeding 90 percent (good to excellent results) (Figs. 1 through 7, *right*). The aesthetic detail among these ears far exceeds the outcome in our patients treated with various stents, tapes, and glues and also surpasses the surgical results in older children. We are reluctant to say that prominent ear deformity has been eliminated with this device, because we believe there is a subset of children that grow into this deformity, possibly manifesting beyond our period of observation. Nevertheless, with this new construct, we have been able to consistently

correct the conchal crus, which we believe is one of the underlying factors in prominent ear deformity. No premature infants or infants less than 4 pounds were treated. One 12-pound infant with very large ears had treatment initiated with the large EarWell device but had to be converted to retention tapes after 2 weeks because of his overly large ears. He had a good but not excellent outcome after 6 weeks. Of the various deformities seen, this system corrects all, with the exception of cryptotia, which is still managed with various molding materials, splints, and stretching devices.<sup>5-9</sup>

Complications have been minor and few. Three patients (5 percent) had localized skin excoriations or breakdown: one in the cymba conchae from the conchal former, one along the helical rim/scapha junction from the retractor system, and one posteriorly in the retroauricular sulcus from the posterior conformer (Fig. 9). There was no cartilage erosion. Each instance of skin injury was caused by the posterior cradle becoming loose and allowing movement and malposition of the internal parts. Tipping of the conchal former onto the fixed “nonfloating” part of the cymba conchae led to the breakdown shown. Parents are now instructed to return to the clinic when the adhesive of the EarWell device begins to loosen, which occurs on average 2 weeks after application. One infant developed an erythematous rash around the ear that required disruption of therapy for 2 days. This rash was diagnosed as monilia skin infection and was treated with topical antifungal cream before reapplication of the EarWell System. In all of these cases, the final outcomes were deemed excellent.

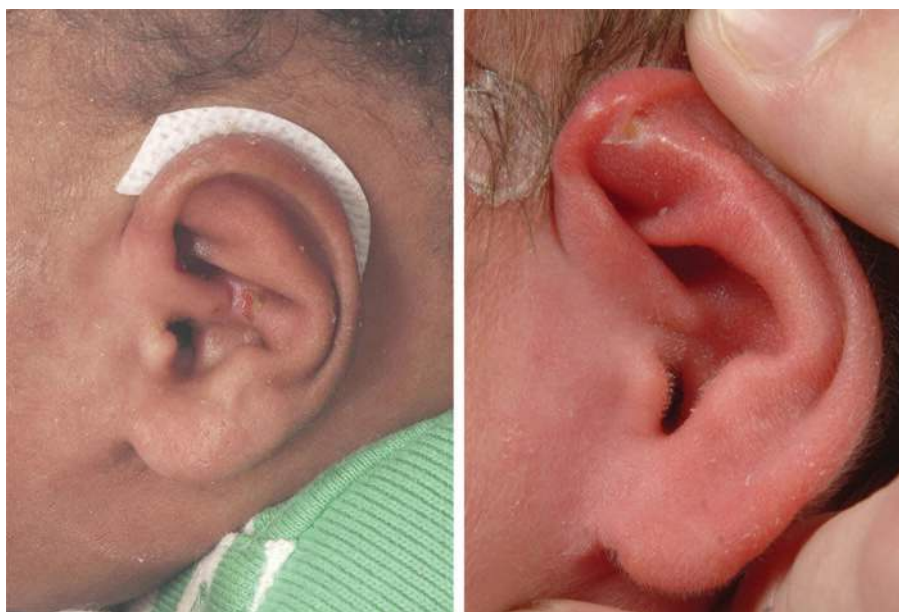## DISCUSSION

It is well established and apparent that the teaching and belief that all infants born with misshapen ears will self-correct is not only wrong but also leads to an indifference to early diagnosis, which may preclude successful nonsurgical treatment with molding. Several ways to splint the deformed ears have been reported, with satisfactory results.<sup>2-4,10-15</sup> Our experience agrees with that of Merlob et al.<sup>16</sup> and a prospective Canadian study<sup>17</sup> where in the former, none of the control infants showed self-correction, and in the latter, 33 percent showed self-correction, most of which occurred early in life. Our recommendation to withhold the molding therapy until the end of the first week is aimed at identifying those infants who may demonstrate self-correction. In our experience, also approximately one-third showed this tendency toward self-correction, whereas the remainder warranted immediate treatment.



**Video.** Supplemental Digital Content 1 demonstrates use of the EarWell, <http://links.lww.com/PRS/A202>.





**Fig. 9.** Minor complications related to the EarWell device. (Left) Skin excoriation in the cymba conchae from the conchal former. (Right) Skin excoriation along the helical rim/scapha junction from the retractor system being placed too close to the posterior conformer.

Several studies minimize the importance of the timing of molding therapy. Yotsuyanagi et al.<sup>9</sup> reported an excellent outcome in over 50 percent of children treated with ear molding with an average age of 3.6 years. It is important to note that over half of the deformities were cryptotias, a deformity in which the cartilaginous framework is normal and only requires expansion of the retroauricular skin. Their average time of molding therapy was 2.1 months, which was longer than in our patients. Muraoka et al.<sup>12</sup> also reported good results in treated patients between 5 months and 5 years old. In contrast, Matsuo et al.<sup>3,18</sup> have shown that deformities of the upper third (lop ear and Stahl's ear) respond to therapy only during the neonatal period, even though protruding ears and cryptotia may respond later. Tan et al.<sup>19</sup> are additional advocates for early diagnosis and initiation of molding therapy. Schonauer et al.<sup>13</sup> recommend waiting 48 to 72 hours after birth before applying their splint. In our study, the outcomes are clearly better when molding is instituted in the first 5 to 7 days of life and less favorable when begun after 3 weeks.

The responsiveness of the ear cartilage is greatest in the newborn because of maternal estrogen.<sup>20</sup> Hyaluronic acid, an important constituent of ear cartilage, is increased by estrogen, and is responsible for the malleable nature of the neonatal ear.<sup>21–25</sup> The circulating estrogen levels decrease rapidly to levels similar to those in older children

by 6 weeks of age.<sup>26</sup> Breast-feeding was felt to extend these levels and require a longer interval for molding, probably secondary to the maternal estrogen in breast milk as previously speculated.<sup>19</sup>

Infants with failed or poor outcomes have been largely limited to the prominent/cup ear category. Some had an associated conchal crus and were treated before the introduction of the conchal former. Others had a family history of prominent ear and, despite a good response to molding, experienced a gradual relapse after therapy was stopped. We now use retention tapes in these infants to extend therapy out to 3 months.

## CONCLUSIONS

Congenital ear deformities are common, and only approximately 30 percent self-correct. These deformities can be corrected by initiating appropriate molding in the first week of life. Neonatal molding reduces the need for surgical correction with results that often exceed what can be achieved with the surgical alternative.

*H. Steve Byrd, M.D.*

Department of Plastic Surgery  
University of Texas Southwestern Medical Center at  
Dallas  
1801 Inwood Road  
Dallas, Texas 75390  
byrd.plasticsurgery@gmail.com

## REFERENCES

1. Tan ST, Abramson DL, MacDonald DM, Mulliken JB. Molding therapy for infants with deformational auricular anomalies. *Ann Plast Surg.* 1997;38:263-268.
2. Kurozumi N, Ono S, Ishida H. Non-surgical correction of a congenital lop ear deformity by splinting with Reston foam. *Br J Plast Surg.* 1982;35:181-182.
3. Matsuo K, Hirose T, Tomono T, et al. Nonsurgical correction of congenital auricular deformities in the early neonate: A preliminary report. *Plast Reconstr Surg.* 1984;73:38-51.
4. Nakajima T, Yoshimura Y, Kami T. Surgical and conservative repair of Stahl's ear. *Aesthetic Plast Surg.* 1984;8:101-107.
5. Dancey A, Jaynes P, Nishikawa H. Acrylic ear splints for treatment of cryptotia. *Plast Reconstr Surg.* 2005;115:2150-2152.
6. Hirose T, Tomono T, Matsuo K, et al. Cryptotia: Our classification and treatment. *Br J Plast Surg.* 1985;38:352-360.
7. Hirose T, Tomono T, Yamamoto K. Non-surgical correction for cryptotia using simple apparatus. In: Fonesca J, ed. *Transactions of the 7th International Congress of Plastic and Reconstructive Surgery, Rio de Janeiro, May 1979.* São Paulo, Brazil: Catgraf; 1980.
8. Park C. Correction of cryptotia using an external stretching device. *Ann Plast Surg.* 2002;48:534-538.
9. Yotsuyanagi T, Yokoi K, Urushidate S, Sawada Y. Nonsurgical correction of congenital auricular deformities in children older than early neonates. *Plast Reconstr Surg.* 1998;101:907-914.
10. Bernal-Sprekelsen M, Krummel FJ. Conservative correction of congenital deformities of the auricle (in German). *Laryngorhinootologie* 1990;69:581-585.
11. Brown FE, Colen LB, Addante RR, Graham JM Jr. Correction of congenital auricular deformities by splinting in the neonatal period. *Pediatrics* 1986;78:406-411.
12. Muraoka M, Nakai Y, Ohashi Y, Sasaki T, Maruoka K, Furukawa M. Tape attachment therapy for correction of congenital malformations of the auricle: Clinical and experimental studies. *Laryngoscope* 1985;95:167-176.
13. Schonauer F, La Rusca I, Molea G. Non-surgical correction of deformational auricular anomalies. *J Plast Reconstr Aesthet Surg.* 2009;62:876-883.
14. Tan ST, Shibu M, Gault DT. A splint for correction of congenital ear deformities. *Br J Plast Surg.* 1994;47:575-578.
15. Ullmann Y, Blazer S, Ramon Y, Blumenfeld I, Peled IJ. Early nonsurgical correction of congenital auricular deformities. *Plast Reconstr Surg.* 2002;109:907-913.
16. Merlob P, Eshel Y, Mor N. Splinting therapy for congenital auricular deformities with the use of soft material. *J Perinatol.* 1995;15:293-296.
17. Smith W, Toye J, Reid A, Smith R. Nonsurgical correction of congenital ear abnormalities in the newborn: Case series. *Paediatr Child Health* 2005;10:327-331.
18. Matsuo K, La Rusca I, Molea G. Non-surgical correction of congenital auricular deformities. *Clin Plast Surg.* 1990;17:383-395.
19. Tan S, Wright A, Hemphill A, Ashton K, Evans J. Correction of deformational auricular anomalies by moulding: Results of a fast-track service. *N Z Med J.* 2003;116:U584.
20. Kenny FM, Angsusingha K, Stinson D, Hotchkiss J. Unconjugated estrogens in the perinatal period. *Pediatr Res.* 1973;7:826-831.
21. Hardingham TE, Muir H. The specific interaction of hyaluronic acid with cartilage proteoglycans. *Biochim Biophys Acta* 1972;279:401-405.
22. Hascall VC, Heinegard D. Aggregation of cartilage proteoglycans: II. Oligosaccharide competitors of the proteoglycan-hyaluronic acid interaction. *J Biol Chem.* 1974;249:4242-4249.
23. Schiff M, Burn HF. The effect of intravenous estrogens on ground substance. *Arch Otolaryngol.* 1961;73:43-51.
24. Uzuka M, Nakajima K, Ohta S, Mori Y. The mechanism of estrogen-induced increase in hyaluronic acid biosynthesis, with special reference to estrogen receptor in the mouse skin. *Biochim Biophys Acta* 1980;627:199-206.
25. Uzuka M, Nakajima K, Ohta S, Mori Y. Induction of hyaluronic acid synthetase by estrogen in the mouse skin. *Biochim Biophys Acta* 1981;673:387-393.
26. Hung W, August G, Glasgow AM. The ovary. In: Hung W, August G, Glasgow AM, eds. *Pediatric Endocrinology.* New York: Medical Examination Publishing; 1978.

## Instructions for Authors: *Update*

### Ethical Approval of Studies/Informed Consent

Authors of manuscripts that describe experimental studies on either humans or animals must supply to the Editor a statement that the study was approved by an institutional review committee or ethics committee and that all human subjects gave informed consent. Such approval should be described in the Methods section of the manuscript. For studies conducted with human subjects, the method by which informed consent was obtained from the participants (i.e., verbal or written) also needs to be stated in the Methods section.

In those situations where a formal institutional review board process is not available, the authors must indicate that the principles outlined in the Declaration of Helsinki have been followed. More information regarding the Declaration of Helsinki can be found at <http://www.wma.net/e/policy/b3.htm>.